



PATIENT

Lizzie Cohen

SPECIES

Canine

BREED

Cavachon

SEX

Female Spayed

PRESENTING CLINICAL SIGNS

History: Presented for heavy breathing. PE revealed a grade 5/6 heart murmur.

-Radiographs: Revealed large amount of ascites on abdominal radiographs and cardiomegaly on chest radiographs. Lungs looked clear.

-Abnormal PE/Chem/CBC/UA Results: Elevated ALP TP 3.0.

ECHOCARDIOGRAM FINDINGS

2D, m-mode, color flow and doppler imaging is available. The mitral valve is thickened with mild prolapse into the left atrial lumen. There is severe eccentric mitral regurgitation present. There is severe left atrial enlargement. There is mild left ventricular dilation. Left ventricular systolic function is hyperdynamic. There is normal systolic flow velocity across the aortic valve. The aortic valve appears thickened yet trileaflet with normal mobility. The main pulmonary artery is moderately dilated. Moderate right atrial and ventricular dilation. The tricuspid valve is thickened with moderate tricuspid regurgitation. Velocity consistent with moderate pulmonary hypertension. Mild pulmonic and no aortic insufficiency. Mild MPA dilation. No pericardial or pleural effusion identified. No cardiac masses are seen.

CARDIAC CHART

AGE

10 years

WEIGHT

23lbs

INTERPRETED BY

Maggie Machen Lamy,
DVM, DACVIM
(Cardiology)

IMAGING PERFORMED BY

Kim Liedberg

HOSPITAL NAME

SVS Imaging WI

REFERRING VET

Dr. Miline

INVOICE

23623

DATE

4/12/22

CANINE CARDIAC PARAMETERS	MR VMAX (m/s)	TR VMAX (m/s)	LA/AO (Boon method)	LA/AO (Heart Base; Swe)	FS (%)	EF (%)	EPSS (cm)
NORMAL PARAMETER	4.5-5.5	<2.7	1.3	<1.6	28-40	40-100	<0.6
PATIENT	5.4	4.0	2.6	2.2	55	90	0.12
CANINE CARDIAC PARAMETERS	HR (BPM)	AV VMAX (m/s)	PV MAX (m/s)	BODY WEIGHT (kg)	LA 2D short axis Base view (cm)	LVIDd Avg; 2D and m-mode short axis (cm)	LVIDs Avg; 2D and m-mode short axis (cm)
NORMAL PARAMETER	50-100	0.7-1.7	0.7-1.6	BELOW	BELOW	BELOW	BELOW
PATIENT	94	1.1	0.8	10.4	3.4	4.4	2.0
*Normal chamber parameters expressed as a mean value (SD)				3	1.27 (5.3)	2.46 (2.46)	1.36 (5.5)
BODY WEIGHT DEPENDENT PARAMETERS				5	1.40 (4.5)	2.74 (5.2)	1.60 (4.7)
<i>*Note: All measurements based upon multi-modal images and methods. An average value is reported.</i>				10	1.50 (3.8)	3.27 (3.5)	2.06 (3.1)
				15	1.83 (2.0)	3.71 (2.4)	2.43 (2.1)
				20	2.02 (1.9)	4.14 (2.2)	2.80 (2.0)
				25	2.18 (2.4)	4.48 (2.9)	3.10 (2.5)
				30	2.33 (3.3)	4.83 (3.9)	3.39 (3.4)
				35	2.48 (4.3)	5.17 (5.0)	3.69 (4.5)
				40	2.62 (5.2)	5.48 (6.1)	3.96 (5.4)
				50	2.88 (7.1)	6.07 (8.3)	4.46 (7.4)

INTERPRETATION OF THE FINDINGS & FURTHER RECOMMENDATIONS

Chronic degenerative valve disease causing severe mitral and moderate tricuspid regurgitation is identified. Severe left atrial and ventricular dilation indicates the risk for spontaneous left-sided congestive heart failure is elevated. Additionally, there is significant right heart enlargement with at least moderate pulmonary hypertension, which puts the patient at risk for right-sided congestion, and/or syncope.

**PATIENT**

Lizzie Cohen

Given the degree of structural disease in addition to ascites, the diagnosis is right-sided CHF and life-long cardiac supportive medications are recommended as below. A baseline ECG and blood pressure are recommended, in addition to repeat radiographs if the symptoms persist despite therapy.

SPECIES

Canine

Omega fatty acid supplementation and mild salt restriction may also be of some long-term benefit. Monitor for development of a worsening cough, labored breathing, exercise intolerance or worsening collapse episodes. Monitoring of sleeping breathing rates is recommended as the best way to screen for progression to CHF at home. Unfortunately, there is high risk for spontaneous CHF, worsening cough and/or malignant arrhythmias and sudden death in the future. The prognosis with this degree of disease is poor, with most dogs able to maintain a good QOL on medications for an average of 8-12 months.

BREED

Cavachon

SEX

Female Spayed

Elective anesthesia is not advised.

PLAN

Initiate spironolactone 1-2mg/kg PO q12h. Institute Sildenafil 1-2mg/kg PO 8h. Administer Lasix 1-2mg/kg PO q12h. Administer Pimobendan 0.3mg/kg PO q12h. Recommend baseline BP, ECG and radiographs as discussed.

AGE

10 years

Recheck renal values and BP in 1-2 weeks, then every 3-4 months on diuretic therapy. If BP is >130mmHg and patient is doing well at home, institute ACEI 0.5mg/kg PO q12h (if hypotensive do not utilize).

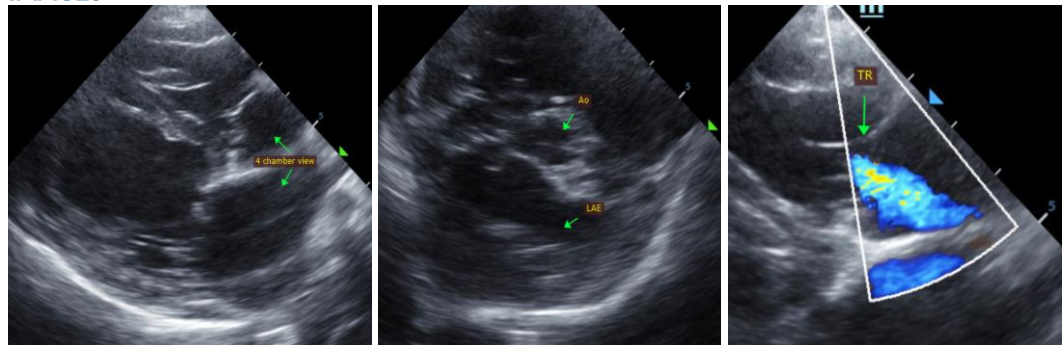
WEIGHT

23lbs

A recheck echocardiogram is recommended in 4-6 months to screen for progression, sooner if clinical signs arise.

INTERPRETED BY

Maggie Machen Lamy,
DVM, DACVIM
(Cardiology)

IMAGES**IMAGING PERFORMED BY**

Kim Liedberg

HOSPITAL NAME

SVS Imaging WI

The information and recommendations provided are based on the images presented by the referring veterinarian. No evaluation can be communicated regarding pathology that was not visible in the image/video clips provided.

REFERRING VET

Dr. Miline

Thank you for this referral. If the clinical or image interpretation does not parallel your findings or if I can be of any further assistance, please contact me.

INVOICE

23623

Maggie Machen Lamy, DVM
Diplomate of the American College of Veterinary Internal Medicine (Cardiology)
info@sonopath.com

DATE

4/12/22